

## PRE-OPERATIVE STAGING OF GASTRIC CARCINOMA

Joksimovic N.,<sup>1</sup> Serafimoski V.<sup>1,2</sup>

<sup>1</sup>*Gastroenterohepatology Clinic, Medical Faculty, Ss. Cyril and Methodius University, Skopje, R. Macedonia*

<sup>2</sup>*Macedonian Academy of Sciences and Arts, Skopje, R. Macedonia*

**Abstract:** This study is a prospective clinical investigation that includes 195 patients (pts), of whom 64 were diagnosed with gastric cancer and endosonographically determined operability.

Endosonography is not used in the primary detection and diagnosis of gastric cancer, but as a supplementary method that, besides the basic detection of the presence or absence of a tumour, gives additional information about the extent of the neoplasm. For this investigation the patients were divided into 3 groups. The first group of 58 pts (30%) were those with benign gastric lesions, 18 pts with polyps and 40pts with gastric ulcers respectively.

The second groups of 64 pts (32.5%) consisted of those with gastric cancer. According to the endosonographic findings this group consisted of 2 subgroups: 45 operable patients and 19 inoperable patients with gastric cancers.

The third group consisted of 73 pts (37.5%) who were without any changes in the gastric wall.

The endosonographic findings in the first subgroup that underwent surgery were correlated with the final intraoperative stage and pathohistology, and in the second subgroup they were compared with the operative finding during the palliation procedure and the final diagnosis of the additional investigation.

All these qualities make this method useful for the diagnosis, control and follow-up of the findings in all of the stadiums of the disease including the post-operative period.

**Key words:** endosonography, gastric carcinoma, pre-operative staging.

### *Introduction*

Gastric cancer is the most frequent malignant disease in both sexes, although its incidence today is decreasing. Current medical sciences have not reached the point of development which will enable an etiological cure for this disease, so that the principal strategy today is aimed at secondary prevention. In order to decrease mortality, a quick and urgent diagnostic approach is necessary, one that includes the operability stage concerning histological finding, and that indirectly influences the prognosis of the disease. The setting of an initial diagnosis of gastric cancer does not completely influence the subsequent treatment. The second phase of clinical investigation includes the determination of the stage of the disease and that is based primarily on the endosonography. [1, 4, 9]

Endoscopic-sonography (EUS) is an indispensable part of diagnostics in the gastrointestinal tract. The gastrointestinal wall is visualized as a five-layered structure on EUS, and this corresponds to the wall's histological layers. It has become practicable to diagnose the local staging of gastrointestinal malignancies using EUS. [8, 10, 11]

Several problems have remained, such as how to differentiate between cancer invasion and ulcer fibrosis, how to detect microinvasion, and how to recognize malignant lymph nodes. EUS-guided fine needle aspiration biopsies have recently been introduced in addition to conventional EUS.

### *Material and methods*

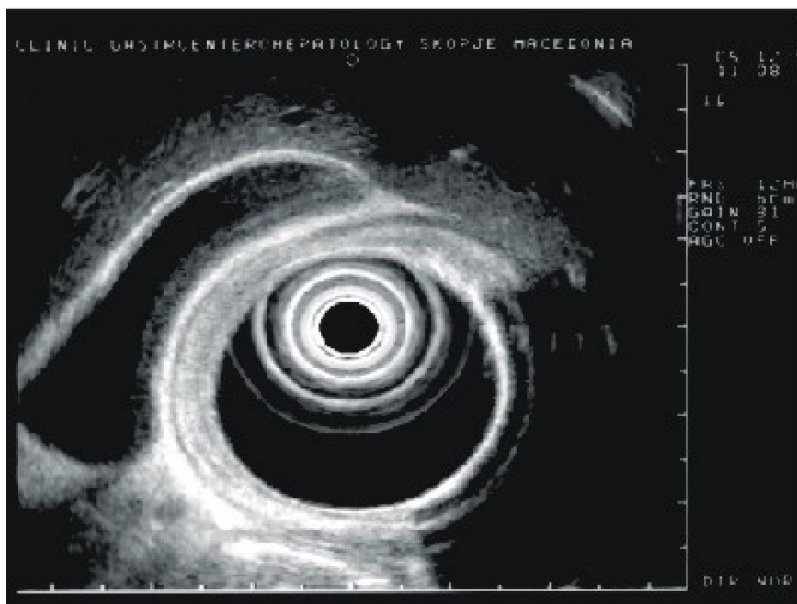
This study is a prospective clinical investigation that includes 195 patients (pts), of whom 64 were diagnosed with gastric cancer and endosonographically determined operability. According to the endosonographic findings, patients were divided into 3 groups:

- patients with benign gastric lesions
- patients with gastric cancer
- control group.

Endosonography is not used in the primary detection and diagnosis of gastric cancer, but as a supplementary method that, besides the basic detection of the presence or absence of a tumour, gives additional information about the extent of the neoplasm. In its supplementary aim, this method has to have sensitivity and specificity close to similar techniques (endoscopy, CT, radiography etc.), and to detect the lesions, which is explicit in this study.

The purpose of the study is to establish the incidence of gastric cancer according to localization and histology; to acknowledge the endosonographic criteria for the differentiation of gastric cancer; preoperative staging for operability/resectability of malignant gastric tumours; statistical evaluation of preoperative endosonography with intraoperative findings and histology; the sensitivity and specificity of the endosonographic method in the stadium determination of gastric cancer; and to establish the survival rate in the operated patient as compared with the stadium according to preoperative sonography. (Fig. 1)

All patients were examined in the left lateral decubitus position and no patient preparation was required. The inserted portion of the transducer was always covered with a disposable balloon prior to gastric insertion. No portion of the gastric mucosa came into direct contact with the endosonography probe (Fig. 1).



*Figure 1 – Endosonographic structure of gastric wall*  
*Слика 1 – Ендосонографски приказ на желудочен ѕид*

Water was then instilled through specially designed orifices in the transducer to permit proper acoustic interfacing between the transducer crystals and the gastric wall. Any residual air within the transducer-balloon interface was removed via the same portals prior to gastric insertion (Fig. 1). The only complications encountered were minimal bleeding in 2 patients. None required therapy. There were no perforations of the gaster.

For this examination we used the endosonography classification for gastric cancer from UICC (Union International Contre le Cancer) and AJCC (American Joint Committee on Cancer) (Table 1)

Table 1 – Табела 1

*Endosonographic classification of gastric cancer*  
*Ендосонографска класификација на желудучној карцином*

St. 0	Tis	No	Mo
St. I	T 1	No	Mo
St. II	T 2–3	No	Mo
St. III	T 1–3	N 1–2	Mo
St. IV	all T	all N	M 0–1

### *Results*

Over a period of five years we carried out conventional EUS imaging of 195 patients (pts), of whom 64 were diagnosed with gastric cancer and endosonographically determined operability. The examinations were carried out on 76 men and 82 women aged on average 57.5 years, (range min 19, max 84, Sd 9.85), in order to prove the anamnestic consideration for gastric disease.

According to the endosonographical findings, patients were divided into three groups: patients with benign gastric lesions; patients with gastric cancer; and a control group.

However, endosonography as a usable supplementary method has to provide sensitivity approximate to the methods to which it is supplementary, in fact to be able to detect the lesion, which was proved beyond doubt in this study. Ultrasonic examination was performed with an EU-M 20 "Olympus" endosonograph with a 12 MHz probe.

Endosonography is not used in the primary detection and diagnosis of gastric cancer, but as a supplementary method that besides the basic detection of the presence or absence of a tumour gives additional information about the extent of the neoplasm. In its supplementary aim this method has to have a sensitivity and specificity close to similar techniques (endoscopy, CT, radiography etc.), and to detect the lesions, which is explicit in this study.

According to investigation the patients were divided in 3 groups. The first group of 58 pts (30%) included those with benign gastric lesions, 18 pts with polyps and 40 pts with gastric ulcers respectively.

The second group of 64 pts (32.5%) included those with gastric cancer. According to the endosonographic findings this group consisted of 2 subgroups: 45 operable patients (Fig. 2) and 19 inoperable patients with gastric cancers. (Fig. 3)

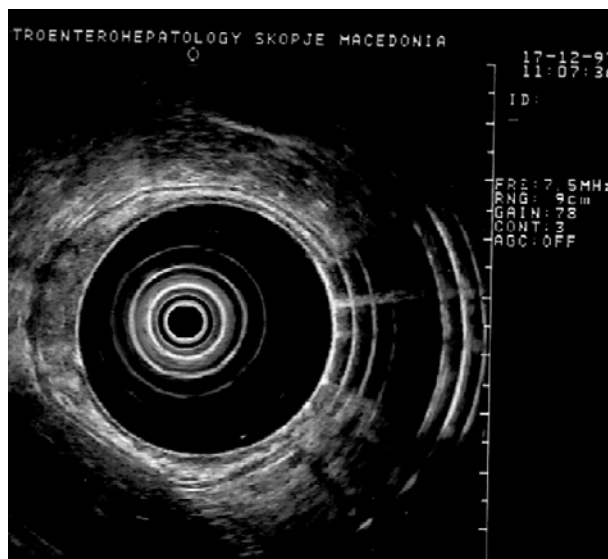

Figure 2 – Endosonographic operable gastric cancer  
Слика 2 – Ендосонографски ојерабилен желудочен карцином

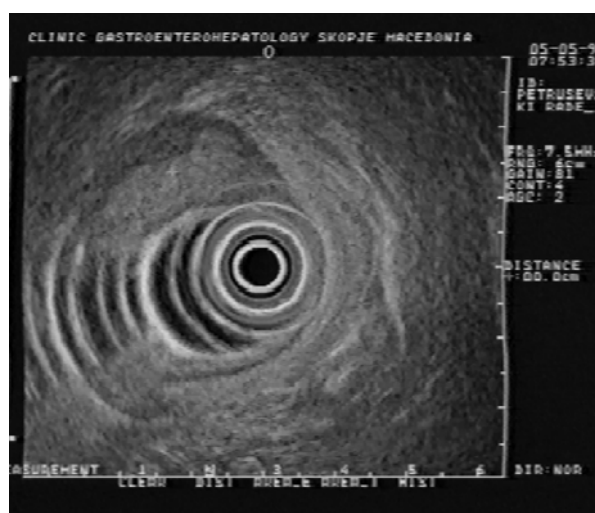


Figure 3 – Endosonographic inoperable gastric cancer  
Слика 3 – Ендосонографски неојерабилен желудочен карцином

The second group of 64 pts (32.5%) included those endosonographically classified as having gastric cancer. According to the endosonography findings this group consisted of 2 subgroups: 45 operable patients (Fig. 2) and 19 inoperable patients with gastric cancers. (Fig. 3) All the patients had radical surgery, and there were 7 pts in TNM stage Ia, 7 pts. In stage Ib, 14 pts in stage II, 17 pts in stage III, and 19 pts in stage IV.

Table 2 – Табела 2

*Endosonographic and operative findings by TNM classification*  
*Ендосонографски наоди и наоди добиени од ојеративниој*  
*мајтеријал класирани по ТНМ класификација*

<b>EUS st./ histology</b>	<b>EUS st.</b>	<b>Histology</b>
st. 0 = st. Ia	7 (11%)	6 (9.0%)
st. I = st. Ib	7 (11%)	8 (12.5%)
st. II = st. II	14 (22%)	15 (23.5%)
st. III = st. IIIa	17 (26%)	16 (25.0%)
st. IV = st. IIIb, IV	19 (30%)	18 + 1 (29% + 1%)
summ	64 (100%)	64 (100%)

The third group of 73 pts (37.5%) was of those without any changes in the gastric wall. This group included 7 pts with peptic oesophageal stenosis, 3 pts with achalasia, 15 pts with oesophageal malignant tumours, 5 pts with a malignant tumour of the main biliary duct, 9 pts with calculosis of the main biliary duct, 6 pts with chronic pancreatitis, 11 with pancreatic pseudocysts, 2 pts with insulinoma and 15 pts with pancreatic neoplasm.

The endosonographic findings in all the patients were compared with the complementary methods (sonography, rentgengraphy, endoscopy, CT scan, etc.). The endosonographic findings in the first subgroup who underwent surgery were correlated with the final intraoperative stage and pathohistology, and those in the second subgroup were compared with the operative findings during the palliation procedure and the final diagnosis of the additional investigation.

The diagnostic and basic values were considered in the operable and inoperable group separately and then summarized for the whole series. The sensitivity was 98% and specificity was 97% with a positive predictive value of 96.5% and a negative predictive value of 98.5%.

### *Discussion*

Preliminary results of EUS have suggested it is an accurate and relatively sensitive technique for the detection of gastric tumour mass, infiltration

into the gastric wall and lymph node involvement [3, 10, 12]. Our study at this time with a large series of patients with surgical proof has shown conclusively that cancer-staging for gastric malignancy is more accurate by EUS ultrasound than by other imaging techniques presently in use.

Although histopathological investigations are indispensable in diagnosing gastric lesions precisely, careful observation of EUS findings, such as the size of the tumour, the internal echopattern, the appearance of the tumour margin and the originating wall layer can help us predict the histopathological nature of tumors [4, 15]. Well demarcated homogeneous hypoechoic tumours located within the fourth layer with or without surrounding lymph-nodes suggest inoperable carcinoma. Unfortunately, precise differentiation between benign and malignant tumors by EUS is impossible.

Nevertheless, there have been many efforts to differentiate between benign and malignant tumours by EUS. Generally, EUS features suggesting a benign tumor were known to be a smaller size and a good demarcation and homogeneity, whereas those suggesting a malignant tumour were known to be larger size, non-homogeneity and irregular margins, destruction of layers, and enlarged surrounding lymph-nodes. In our study, the diagnostic accuracy of EUS in the differential diagnosis between benign and malignant tumours based on the above-mentioned criteria was 82.5%.

However, because EUS cannot replace histology, EUS diagnosis concerning the histopathological nature of tumours is imprecise, but it is indubitable that EUS is superior to other conventional diagnostic modalities for the differential diagnosis of gastric cancer, including endoscopy, barium study and CT scan.

### *Conclusion*

Endosonography is highly significant in the staging of gastric cancer, the follow-up and evaluation of gastric wall infiltration, determining the intramural infiltration borders and the detection of the metastasis of lymph nodes that influences the postoperative prognosis. The method is precise, with a high degree of specificity and sensitivity, simple, cheap, practical, needing no special preparations for the patients and medical stuff, and nonaggressive. All these qualities make this method useful for the diagnosis, control and follow-up of the findings in all of the stadiums of the disease including the post-operative period.

### REFERENCES

1. Abe S., Yoshimura H., Nagaoka S., Monden N., Kinugasa S., Nagasue N., Nakamura T. (2003): Long term results of the operation for carcinoma of the stomach in

T1/T2 stages; critical evaluation of the concept of early carcinoma of the stomach. *J Am. Coll Surg*; 181: 389–396.

2. Ahlman H., Kolby L., Lundell L., Olbe L., Wangberg B., Granerus G., Grimelius L., Nilsson O. (1999): Clinical management of gastric carcinoid tumors. *Digestion*, supp; 55: 77–85.

3. Caletti G., Odegard S. S., Rosch T., Sivak M. V., Tio Tl., Yasuda K. (2004): Endoscopic ultrasonography (EUS), A summary of the conclusions of the working party for the tenth world congress of gastroenterology Los Angeles, California. *Am. J. Gastroent*; 89: 138–143.

4. Kimmey M. B., Martin R. W. (1992): Fundamentals of endosonography. *Gastrointest Endosc. Clin N Am*; 2: 557–573.

5. Lee A., Dixon M. F., Danon S. J., Kuipers E., Megraud F., Larsson H., Mellgrad B. (1995): Local acid production and helicobacter pylori, a unifying hypothesis of gastroduodenal disease. *Eur. J. Gastroenterol. Hepatol*; 7: 461–465.

6. Maruyama M. (1992): *Early Diagnosis of Gastrointestinal Cancer; double contrast gastrointestinal radiology*. WB Saunders Co. Philadelphia; 496–532.

7. Murakami T. (1979): Early cancer of the stomach. *World J. Surg*; 3: 685–692.

8. Nakamura T., Nakano G. E. (1985): Histopathological classification and malignant change in gastric polyps. *J. Clin. Pathol*; 38: 754–764.

9. Palazzo L., Roseau G., Ruskone A. (1993): Endoscopic ultrasonography in the local staging of primary gastric lymphoma. *Endoscopy*; 25: 502–508.

10. Tio T. L., Kallamans G. E. (1994): Endoscopic ultrasonography of perigastrointestinal lymph nodes. *Endoscopy*; 26: 776–779.

11. Tytgat G. N. J., Fockens P. (1992): Endoscopic ultrasonography. *Scand. J Gastroenterol*; 27: 80–87.

## Резиме

### ПРЕДОПЕРАТИВНИОТ СТЕЈДИНГ НА ЖЕЛУДОЧНИОТ КАРЦИНОМ

**Јоксимовиќ Н.<sup>1</sup> Серафимоски В.<sup>1,2</sup>**

<sup>1</sup>Клиника за гастроентеро-хепатологија, Медицински факултет,  
Универзитетот Св. Кирил и Методиј, Скопје, Р. Македонија

<sup>2</sup>Македонска академија на науките и уметностите, Скопје, Р. Македонија

Трудот претставува проспективна клиничка студија на 195 пациенти, од кои кај 64 е дијагностициран желудочен карцином, при што операбилноста

е определена ендосонографски. Ендосонографијата не е користена во примарната детекција и дијагностика на желудочните карциноми, туку како суплементарен метод кој, покрај основниот податок за присуство или отсуство на тумор, дава дополнителни податоци за екстензитетот на неопластичната лезија.

Според севкупните наоди, пациентите беа поделени во три групи. Првата група од 58 (30%) ја сочинуваа пациенти кај кои ендосонографски се утврди постоење на бенигни лезии на желудникот, и тоа 18 пациенти со полипи и 40 со улкуси на желудникот.

Втората група од 64 (32,5%) ја сочинуваа пациенти со дијагностицирани желудочни малигноми. Според ендосонографските наоди, оваа група е поделена на две подгрупи: 45 пациенти со ендосонографски операбилни желудочни карциноми и 19 со ендосонографски неоперабилни желудочни карциноми.

Третата група од 73 пациенти (37,5%) се оние испитаници кај кои ендосонографски не се видени промени на сидот на желудникот во смисла на малигна инфилтрација. Пациентите со ендосонографски наоди за операбилен карцином на желудникот беа споредувани со дефинитивните интраоперативни и патохистолошки наоди. Групата пациенти со ендосонографски наод за неоперабилен желудочен карцином е споредена со оперативниот наод кај палијативно оперираните, како и со финалната дијагноза добиена со други, дополнителни испитувања.

Методот е сигурен, со висок степен на сензитивност и специфичност, лесен за изведување, евтин, не бара посебни услови за работа или подготовка на испитаниците и не е штетен за здравјето на болниот и на персоналот, што го чини погоден за дијагностика, контрола и следење на наодите во сите фази на болеста, како и постоперативно.

**Клучни зборови:** ендосонографија, карцином на желудник, предоперативен стејџинг.

**Corresponding Author:**

**Joksimovic Nenad**  
**Clinic of Gastroenterohepatology,**  
**Medical Faculty**  
**Vodnjanska 17**  
**1000 Skopje, R. Macedonia**  
**Tel. ++ 389 2 3147-134**  
**Fax. ++ 389 2 3111-229**

**E-mail: nenadjoksimovic@yahoo.com**